

Diagnostic challenges and therapeutic implications of Hyperostosis Frontalis Interna (HFI) in a post-menopausal woman - A case report

Prabhudev M Hiremath¹, Anish Mehta¹, Rakshith Srinivasa², Pradeep R.1, Mahendra Javali¹, R. Srinivasa³

¹Department of Neurology, Ramaiah Medical College and Hospitals, Ramaiah University of Applied Sciences, Bengaluru, India

²Department of Neurosurgery, Ramaiah Medical College and Hospitals, Ramaiah University of Applied Sciences, Bengaluru, India

³Aster CMI Hospital, Bengaluru, India

ABSTRACT

This case report highlights the importance of recognizing Hyperostosis Frontalis Interna (HFI) in patients with a diverse clinical presentation, particularly in post-menopausal individuals with relevant risk factors. It emphasizes the need for maintaining a high index of suspicion in neurological settings. Timely identification and treatment of HFI can significantly improve patient outcomes and alleviate debilitating symptoms and comorbidities. HFI, often an under-diagnosed condition and an incidental radiological finding, calls for ongoing research and vigilance in clinical practice.

Keywords: Hyperostosis Frontalis Interna, diagnosis, neurological symptoms, post-menopausal

INTRODUCTION

Hyperostosis Frontalis Interna (HFI), also known as Morgagni-Stewart-Morel syndrome, is a rare condition characterized by abnormal thickening of the frontal bone of the skull [1]. This condition has been previously associated with metabolic, endocrine, and genetic factors [1]. However, its clinical presentation often lacks specificity, which can lead to potential misdiagnosis or delayed recognition [1,2]. This case report focuses on a 61-year-old individual of Indian descent with a history of hypothyroidism and type 2 diabetes mellitus. She presented with a complex array of neurological and behavioral symptoms, initially misdiagnosed as seronegative autoimmune encephalitis. The diagnosis of HFI was made incidentally through radiographic observations of frontal bone thickening. Subsequent surgical intervention led to significant clinical improvement. This case underscores the importance of recognizing this often overlooked and potentially treatable condition, particularly in post-menopausal individuals.

CASE PRESENTATION

A 61-year-old individual of Indian descent with obesity, a history of hypothyroidism, and type 2 diabetes mellitus, as well as a 20-year long seizure disorder under remission, presented to our neurology clinic with a complex array of symptoms that progressively worsened over the course of the past one year. Specifically, the individual experienced recurrent episodes of involuntary tonic-clonic movements in all four limbs, often accompanied by up-rolling of the eyes and a transient loss of consciousness lasting for several seconds to minutes, semiology suggestive of generalized tonic-clonic seizures (GTCS). Additionally, the patient experienced occasional episodes of brief loss of awareness and unresponsiveness lasting for a few seconds to minutes. Furthermore, the individual experienced a range of behavioral disturbances which included loss of initiation, decreased motivation, reduced verbal output, behavioral slowness (abulia) along with increased agitation and impulsivity. Emotional lability, reduced social interaction, and mood disturbances were also ob-

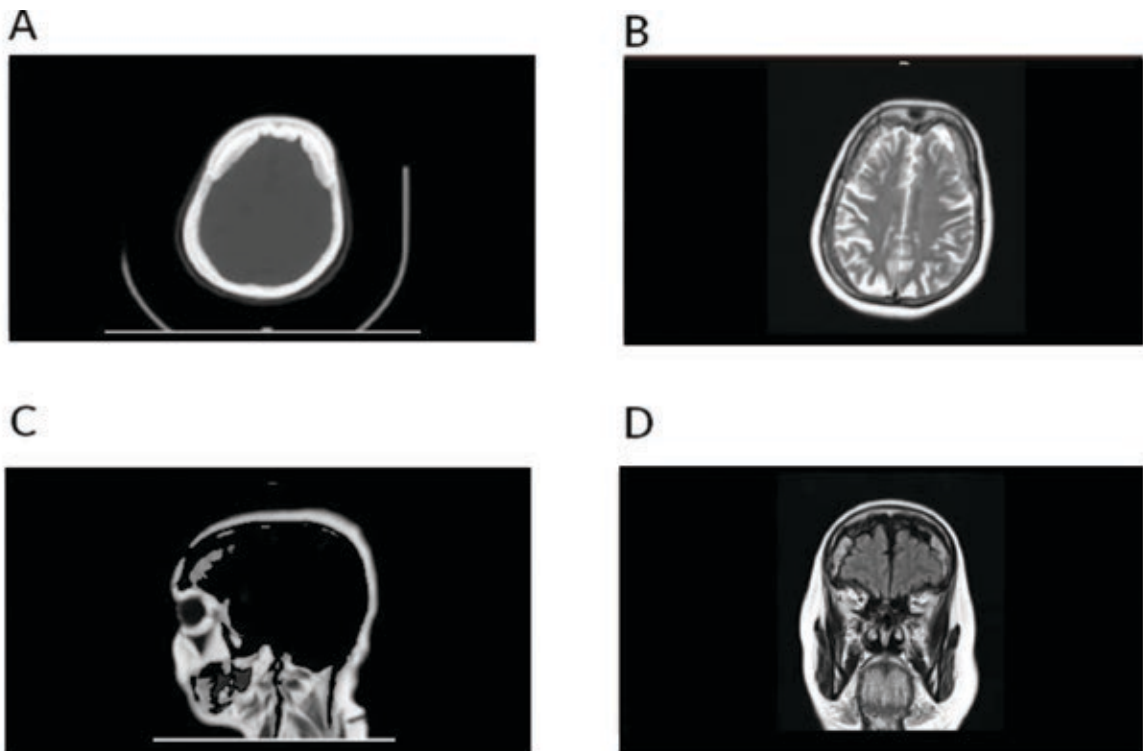


FIGURE 1. CT and MRI Brain Plain Images

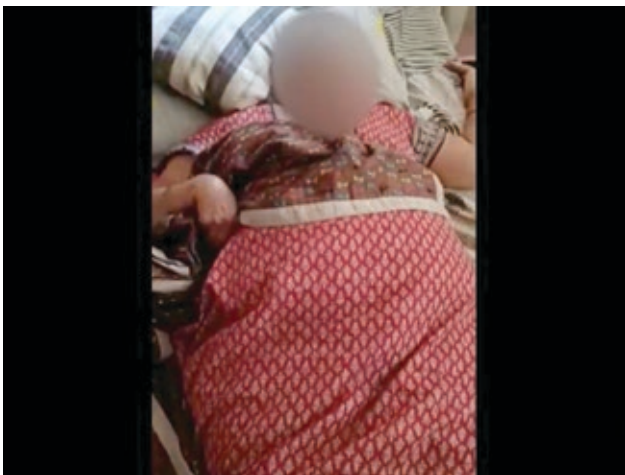
A : CT Brain Plain bone cuts; B, C and D: MRI Brain Plain T2 axial image, T1 sagittal image and T1 coronal image showing HFI Type D

served. This person also experienced a gradual decline in mobility. From being able to walk with minimal support, her condition progressively deteriorated, and she was barely able to stand or walk without support during the initial presentation to our clinic (video 1; segment 1). The individual also experienced urinary incontinence for about a year and required the use of diapers and was also unable to indicate the need for micturition to family and care givers. In the past, the individual was diagnosed with seronegative autoimmune encephalitis at another hospital and was treated with pulse IV methylprednisolone (1 gm infusion for 5 days), IVIG (2 g/kg infusion over 5 days), antiepileptic medications, antipsychotics and other symptomatic therapy. However, there were no improvements and the condition continued to worsen.

The patient was admitted for re-evaluation, clinical examination noted no abnormalities with respect to vital signs. A thorough neurological examination revealed that she experienced spatial disorientation and was slow to respond to verbal commands and exhibited palilalia (repetitive utterances). The individual also exhibited stereotypical hand movements and abnormal grasp reflex (video 1; segment 1). There were no apparent cranial nerve abnormalities. While motor power appeared normal, she was found to have increased muscle tone in all four limbs. However, deep tendon reflexes were within normal limits with plantar reflex bilateral flexor response and there were no cerebellar signs. Gait examination re-

vealed she was able to stand with two people's support and was barely able to walk. A thorough diagnostic evaluation was carried out, encompassing a range of laboratory tests, including complete blood count, liver function tests, renal function tests, serum calcium, thyroid profile, and serum electrolytes. Additionally, an immune workup was performed, which involved assessing anti-thyroid peroxidase antibodies (anti-TPO), thyroglobulin antibodies (TgAb), HIV status, VDRL for syphilis, anti-nuclear antibodies immunofluorescence (IF) profile and serum autoimmune antibody panel and serum paraneoplastic antibody panel all of which yielded negative results.

A lumbar puncture was performed to analyze cerebrospinal fluid (CSF), both for routine examination and to check for infectious markers. The results from these CSF analyses showed no abnormalities. Furthermore, serum tests for Neuromyelitis Optica (NMO) antibodies and Myelin oligodendrocyte glycoprotein (MOG) antibodies were negative. The CT and MRI Brain (Plain with contrast) showed brain parenchyma was unremarkable (Figure 1). It was noted that the frontal bone of the skull had thickened, leading to the compression of the frontal lobe. This clinical presentation with a distinctive observation of frontal bone thickening raised suspicion for Hyperostosis Frontalis Interna (HFI). Subsequently, after discussion with the neuroradiologist, it was noted that the patient had Type D HFI, and the observed symptoms were attributed to frontal lobe compression as a consequence of this condition.



VIDEO 1. Clinical course of HFI presentation and post-treatment outcomes

Serial Electroencephalogram (EEG) studies showed diffuse generalized background slowing with occasional bifrontal sharp wave discharges seen.

After discussing the various treatment options with the patient's family and obtaining their informed consent, frontal lobe decompression and cranioplasty were performed (Figure 2). Postoperative recovery was favorable, with noticeable improvements in behavior and gait (video 1; segment 2), which were observed within 15 days post-surgery. A repeat EEG after surgery indicated the absence of epileptiform dis-

charges and improved background activity. Antiepileptic medications were optimized by reducing both the dosage and the number of antiepileptic drugs (AEDs). The individual is currently under follow-up care and is doing well, requiring minimal assistance for activities of daily living (video 1; segment 2).

DISCUSSION

Consistent with previous findings in the medical literature [2,3], the case report presented here underscores the significance of maintaining a high level of suspicion for HFI in neurological settings, especially in postmenopausal individuals, who present with new or late-onset neurological symptoms and possess risk factors associated with HFI. The initial misdiagnosis of seronegative autoimmune encephalitis highlighted in this case report indicates that HFI can often mimic other neurological or psychiatric conditions due to its non-specific clinical manifestations [4]. It's worth noting that HFI predominantly affects postmenopausal individuals, and the characteristic thickening of the frontal bone may not be immediately apparent during a routine clinical examination, often only becoming evident as an incidental radiographic finding [4]. Therefore, it's essential to maintain a heightened awareness when assessing individuals with neurological and behavioral disturbances, particularly those who have not responded to standard treatments.

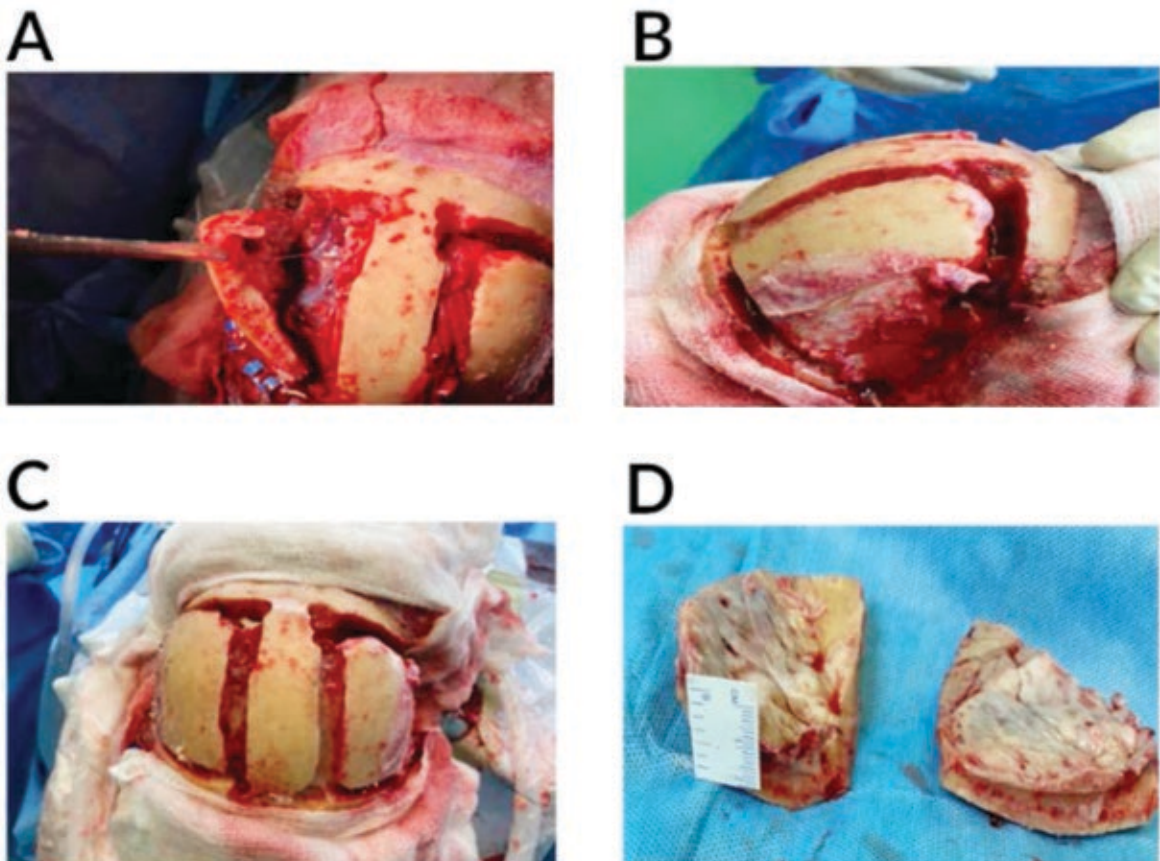


FIGURE 2. Surgical Images of Frontal lobe decompression and craniotomy

This case report emphasizes the importance of recognizing individuals with HFI as they may be asymptomatic to have diverse clinical presentations especially in postmenopausal individuals. The recurrence of seizures in our patient, despite a decade of control, prompted further investigation to identify an underlying cause. Moreover, individuals with HFI may exhibit a wide range of behavioral disturbances, including emotional lability, reduced social interaction, mood disruptions, and progressive cognitive decline [5]. Healthcare professionals should consider the potential of HFI when encountering these clinical features.

While the precise etiology of HFI remains unclear, potential risk factors encompass hormonal influences, metabolic factors, and genetic predispositions (1). HFI has been linked to excessive calcium deposition and cranial bone remodeling [4]. This raises questions about the impact of excessive calcium intake and supplementation, particularly in post-menopausal individuals, rather than focusing on one gender. In our patient, we observed the use of over-the-counter calcium and vitamin D3 supplements for more than two years. The existing body of literature is limited in definitively establishing the role of excessive calcium supplementation in HFI, underscoring the need for further research in this area.

REFERENCES

1. Raikos A, Paraskevas GK, Yusuf F, Kordali P, Meditskou S, Al-Haj A, et al. Etiopathogenesis of hyperostosis frontalis interna: A mystery still. *Annals of Anatomy - Anatomischer Anzeiger*. 2011;193(5):453–8. doi: 10.1016/j.aanat.2011.05.004.
2. Attanasio F, Granziera S, Giantin V, Manzato E. Full penetrance of Morgagni-Stewart-Morel syndrome in a 75-year-old woman: case report and review of the literature. *J Clin Endocrinol Metab*. 2013;98(2):453–7. doi: 10.1210/jc.2012-3242.
3. Torrealba-Acosta G, Mandel J. Hyperostosis frontalis interna diagnosed after a provoked seizure. *BMJ Case Rep*. 2020;13(7):e236520. doi: 10.1136/bcr-2020-236520.
4. Stiene JM, Frank PW. Hyperostosis Frontalis Interna and a Question on Its Pathology: A Case Report. *Am J Case Rep*. 2022;23:e937450-1-e937450-4. doi: 10.12659/AJCR.937450.
5. Carr AD. Neuropsychiatric Syndromes Associated with Hyperostosis Frontalis Interna. *Arch Neurol Psychiatry*. 1936;35(5):982–9. doi: 10.1001/archneurpsyc.1936.02260050056004.

CONCLUSION

Recognizing the diverse clinical presentation of HFI and maintaining a high index of suspicion, especially in post-menopausal individuals, can lead to earlier diagnosis and intervention. This case report underscores the necessity for vigilance in clinical practice to address the challenges posed by HFI, a frequently under-diagnosed condition and an incidental radiological finding in neurological settings.

Patient consent:

A consent was obtained from the patient and her family member for publishing the details of this case report.

Conflict of interest: none declared

Financial support: none declared

Authors' contributions:

- Anish Mehta: Conceptualization, Methodology.
 Prabhudev M Hiremath: Data curation, Writing- Original draft preparation.
 Rakshith Srinivasa: Investigation and Treatment.
 Pradeep R: Supervision.
 Mahendra Javali: Reviewing and editing original draft.
 Purushottam Acharya: Writing- Reviewing and Editing.
 R Srinivasa: final approval of the published version