

CEREBELLAR AND BRAINSTEM INFARCTION SECONDARY TO BASILAR ARTERY DOLICHOECTASIA

Anca Motataianu^{1,3}, Laura Barcutean^{1,3}, Ioana Gherman¹, Smaranda Maier^{1,3},
Zoltan Bajko^{1,3}, Adrian Balasa^{2,3}

¹Neurology 1 Clinic, Emergency Clinical County Hospital, Targu Mures, Romania

²Neurosurgery Clinic, Emergency Clinical County Hospital, Targu Mures, Romania

³“George Emil Palade” University of Medicine, Pharmacy, Science and Technology Targu Mures, Romania

ABSTRACT

Vertebrobasilar dolichoectasia (VBD) is a rare condition characterized by a significant dilation, elongation and tortuosity of the arteries emerging from the vertebrobasilar system. In this study, we report a 57-year-old male, with medical history of recurrent migraines and right peroneal nerve palsy, which presents the sudden onset of clinical signs of brainstem and cerebellar stroke. The brain CT scan revealed an inhomogeneous, hyperdense prepontine lesion, situated in the area of basilar artery (BA) projection. The cerebral angiography showed in the V4 segment of the left vertebral artery (VA) a focal, concentric stenosis of 70%, followed by a fusiform dilation extended to the BA bifurcation, a saccular aneurysmal dilation in the communicant segment of the internal carotid artery and tortuous trajectory of the abdominal and thoracic aorta, including the supra-aortic vessels. The brain MRI revealed a bulbopontin and left cerebellum infarction. Patient developed at 48 hours after hospitalization livedo reticularis at the level of the right thoracic wall and thighs. The nerve conduction studies revealed mononeuritis multiplex.

The vascular anomaly that was identified in the presented case respects the criteria for a VBD, however the involvement of the aorta with the presence of tortuosities, the simultaneous presence of the internal carotid artery aneurysm, together with the presence of the mononeuritis multiplex and the skin condition (livedo reticularis) suggest the possibility of coexistence of a systemic vasculitis, possible polyarteritis nodosa.

Keywords: dolichoectasia, vertebrobasilar arterial system, brainstem and cerebellar stroke

INTRODUCTION

Vertebrobasilar dolichoectasia (VBD) is a rare condition characterized by a significant dilation, elongation and tortuosity of the arteries emerging from the vertebrobasilar system (1). In the general population, the prevalence is reported under 0.05% (1,2).

Initially, VBD can be asymptomatic. The onset is marked by either an acute vertebrobasilar stroke or by a massive brain haemorrhage secondary to vascular rupture, usually fatal. In rare cases, it can be diagnosed due to a slowly progressive onset characterized by clinical signs of brainstem and cranial nerves compression (3,4,5,6).

VBD can associate various vascular abnormalities such as abdominal aortic aneurysms or saccular intracranial aneurysms (7,8). The main pathophysiological characteristic of VBD is the involvement of the medial layer of the intracranial vessels, with the presence of the intraluminal thrombi, and not the intimal layer, as described in dilatative atherosclerotic lesions (4).

Cerebral aneurysms, including VBD, have been associated with numerous disorders such as type IV Ehler-Danlos syndrome, Marfan syndrome, fibromuscular dysplasia, Fabry disease, autosomal dominant polycystic kidney disease, disseminated systemic lupus erythematosus and other vasculitides (9,10). Primary systemic vasculitides that mainly

involve the central nervous system (CNS) in adult patients are polyarteritis nodosa (PAN), Wegner granulomatosis, Behçet disease and Takayasu arteritis. The secondary vasculitides associated with the systemic inflammatory diseases, like in lupus erythematosus, Sjögren syndrome, Crohn disease and sarcoidosis (11).

CASE PRESENTATION

We present the case of a 57-year-old male patient, with a history of recurrent migraines and right peroneal nerve palsy, which presents the sudden onset of a right limb deficit and dysarthria, symptoms that progressed in the first hours after the onset. The neurological exam at the admittance showed a patient with right flask hemiplegia, posterior internuclear ophthalmoplegia, left peripheral facial palsy, left hypoacusia, hypomobile vellum with abolished deep throat reflexes, severe swallowing impairment for both liquids and solids, deviation of the tongue to the right in protrusion, anarthria, dysmetria in the left upper limb, right Babinski's sign, superficial right hemihypesthesia, drowsiness, with a NIHSS of 15 points. In evolution, he presented with an altered state of consciousness, obnubilation and stupor, GCS 9 points (M4, V2, O3).

The brain CT scan revealed an inhomogeneous, hyperdense prepontine lesion, situated in the area of basilar artery (BA) projection (Figure 1a). The angio-CT scan of the cerebral arteries confirmed the presence of a fusiform aneurysm, 18 mm in di-

ameter and 40 mm long, partially thrombosed at the level of the BA, associated with a saccular aneurysmal dilation in the communicant segment of the internal carotid artery, 7 mm in diameter (Figure 1b). The brain MRI revealed a bulbopontin and left cerebellum stroke (Figure 1c). The Doppler ultrasound examination revealed no particularities of the extracranial arteries.

The cerebral angiography (Figure 2) revealed in the V4 segment of the left vertebral artery (VA) a focal, concentric stenosis of 70%, followed by a fusiform dilation extended to the BA bifurcation. The angiography also revealed a tortuous trajectory of the abdominal and thoracic aorta, including the supra-aortic vessels and a saccular aneurysmal dilation in the communicant segment of the internal carotid artery.

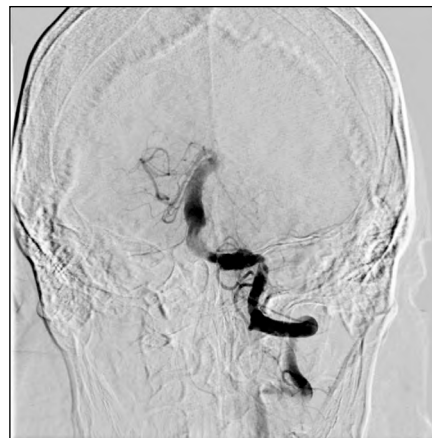

FIGURE 2. Cerebral angiography: left VA, V4 segment, a concentric focal stenosis of 70%, followed by an extensive fusiform aneurysmal dilation, extended until the bifurcation of the BA

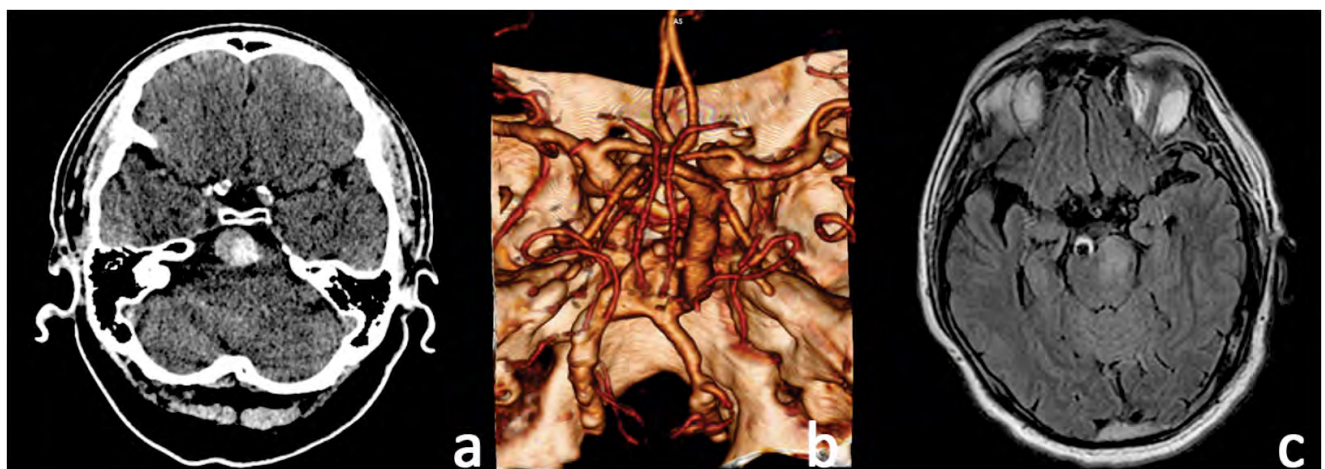


FIGURE 1 – a. The brain CT scan – hyperdense, inhomogeneous prepontine lesion, situated in the area of BA. **b.** Angio-CT scan reveals a fusiform dilation (aneurysm), 18 mm diameter and 40 mm long, partially thrombosed of the BA, associated with a saccular aneurysmal dilation of the communicant segment of the left internal carotid artery, 7 mm in diameter. **c.** Brain MRI – pontine infarction

The EKG showed normal sinus rhythm. The extended immunological and infectious panel included ESR, antinuclear antibodies (by indirect immunofluorescence), anti β 2 microglobulin antibodies, C3, ANCA, IgG anticardiolipin antibodies, anti DNA double-stranded antibodies, lupus cells, rheumatoid factor, HIV, TPHA, hepatic viruses were all negative. The CT and angio CT scan of the thorax and abdominal region revealed a supradiaphragmatic aortic kinking. The nerve conduction studies (NCS) revealed mononeuritis multiplex.

During the admittance, the patient presents livedo reticularis at the level of the right thoracic wall and thighs, remitted under hydrocortisone hemisuccinate. After the cessation of the cortisone agent, the lesions promptly reappeared in the posterior aspect of the thorax, upper limbs and thighs, bilaterally.

The treatment included antiplatelet, anticoagulant with low molecular weighed heparin for thromboprophylaxis, cerebral depletion, hydrocortisone, neuromotor and logopedic rehabilitation. The evolution was favourable, the patient was discharged with left peripheral facial palsy, recovery of deglutition for both solids and liquids, right side hemiparesis 1/5 MRC, right hemihypesthesia, dysarthria, Rankin 4 points.

The evolution at 6 months was favourable, with a partial recovery of the neurological deficits, the patient being able to walk with unilateral support, right side hemiparesis 3/5 MRC.

DISCUSSION

We sought to present a case that paints the complex clinical picture of VBD, a relatively rare pathology, characterized by the expansion, elongation and tortuosity of the vertebrobasilar arteries (1). The prevalence of VBD in stroke patients is between 3 and 17% (10,12,13). An extended meta-analysis by Wolters FJ et al. (2013), that included 375 VBD patients, reported a significant incidence of the ischemic events at the onset of the disease, over 30%, followed by brainstem symptoms secondary to compressive phenomena. At the 5-year follow up there was an increasing trend of complications, 17% for vertebrobasilar ischemic strokes, 3% for hemorrhagic events and 3% for hydrocephalus (14).

In order to establish the VBD diagnosis, the following criteria must be met in the brain CT scan: 1) the BA diameter > 4.5 mm, 2) a lateral trajectory of the BA towards the clivus or dorsum sellae, in the suprasellar cisterns or towards the third ventricle, 3) high bifurcation, over the dorsum sellae, at the level of the suprasellar cisterns or the third ventricle (15). Additionally, the length of the BA > 29.5 mm, together with the length of the VA in the intracranial segment > 23.5 mm aids the diagnosis (16). The vascular anomaly that was identified in the presented case respects the criteria for a VBD, however the involvement of the aorta with the presence of tortuosities, the simultaneous presence of the internal carotid artery aneurysm, together with the presence of the mononeuritis multiplex and the skin condition (livedo reticularis) suggest the possibility of a systemic vasculitis. Due to the associations between the mononeuritis multiplex together with the cutaneous involvement and angiographic changes, the co-diagnosis of PAN can be considered.

The data is relatively scarce regarding the prognostic, natural evolution and the prevention of ischemic complications of VBD. The factors that aid to the development of VBD are under debate, but advanced age, male sex and hypertension have been associated with the evolution of this disorder (6,17,18).

The physiopathology behind the stroke secondary to VBD is determined by the existence of an anterograde abnormal laminar blood flow which predisposes to the formation of luminal thrombi, with or without associated embolic events or occlusion of the small, penetrating vessels that emerge from the VBD's main dilation (by widening the arterial wall/small vessel vasculopathy) (18-21). Histopathological studies demonstrated that there are significant differences comparing the atherosclerotic lesions and lesions in VBD. In atherosclerosis, the thickening of the intima is constant, while in VBD the fragmentation of the internal elastic layer with a narrowing of the medial layer is present (4,22,23).

The overall risk of stroke and intraparenchymatous brain haemorrhage increases as the VBD widens, which makes the management even more challenging. Considering that, at the moment, there are no standardized treatment guides, VBD manage-

ment needs to be considered individually, in order to reduce the thrombotic risk without increasing the haemorrhaging risk, taking into account that the presence of the aneurisms predisposes the patient to subarachnoid or intraparenchymal haemorrhages.

The cerebral involvement is described in PAN, but the onset with CNS symptoms has been rarely reported (24). CNS symptoms tend to appear 2-3 years after the diagnosis, and in 10% of the cases, it manifests as a stroke (25). Frequently, in PAN, peripheral neuropathy is present as mononeuritis multiplex or polyneuropathy, in 65-80% of the cases (26). Although in our case the first manifestation was stroke, we extended the differential diagnosis in order to identify a secondary aetiology to vessel involvement, one that has a treating potential. The imaging studies in PAN reveal tortuous vessels and microaneurysms (27). Visceral arteries involvement is predominant, together with limb and aortic vessels. The cerebral angiography usually reveals aneurysms and stenosis/occlusion of the carotid arteries in the intracranial segment (28,29). Segmental artery occlusion/stenosis, with a predilection for branching and bifurcations, is characteristic (29). The imaging aspects that sustain the PAN diagnosis in our case are the stenosis of the left VA, the wide fusiform aneurysms that involves the bifurcation of the BA and the saccular aneurysm of the left internal carotid artery, 7 mm in diameter. The angiography did not reveal significant changes in the pulmonary, renal and mesenteric arteries, which are pathognomonic for PAN.

The American College of Rheumatology declares that, for the diagnosis of PAN, 3-4 criteria from the following list are needed: weight loss of minimum 4 kg in the past year, livedo reticularis,

testicular pain, myalgia or muscle weakness, mononeuropathy/polyneuropathy, diastolic blood pressure higher than 90mmHg, high creatinine or urea levels, positive serology for hepatitis B, specific angiographic aspects (30) and positive biopsy (31). In our case, two criteria are met, the angiographic aspect and the presence of the mononeuritis multiplex. Considering the fact that our patient doesn't have acute organ insufficiency or any other associated pathologies, the biopsy was not performed during hospitalization.

We also considered various pathologies that are usually associated with brain aneurysms and with VBD. Hepatitis B and C, HIV infection, syphilis are all important causes of vasculitis and VBD (32). The infectious panel excluded all these pathologies. We also excluded LES with CNS involvement and autosomal dominant polycystic kidney disease due to normal CT aspect.

CONCLUSIONS

While we may refer to an increase of the diameter of the BA as a fusiform aneurysm or a DVB, in the present case we suspected an associated systemic vascular involvement. Even though the criteria for PAN are not met, the diagnosis of systemic vasculitis shouldn't be neglected, the reason for which we are considering an overlap, between VBD and PAN.

VBD is a complex arterial pathology that encompasses a large spectre of vascular anomalies with a variable clinical impact and which, in dynamic, can lead to stroke, hemorrhagic complications or compressions and rises important therapeutic and diagnostic dilemmas.

REFERENCES

1. Yuan YJ, Xu K, Luo Q et al. Research Progress on Vertebrobasilar Dolichoectasia. *Int J Med Sci.* 2014; 11(10):1039-1048.
2. Flemming KD, Wiebers DO, Brown RD Jr et al. The natural history of radiographically defined vertebrobasilar nonsaccular intracranial aneurysms. *Cerebrovasc Dis.* 2005;20(4):270-279.
3. Shapiro M, Bekske T, Riina HA et al. Non-saccular vertebrobasilar aneurysms and dolichoectasia: A systematic literature review. *J Neurointerv Surg* 2014; 6(5):389-393.
4. Lou M, Caplan LR. Vertebrobasilar dilatative arteriopathy (dolichoectasia). *Ann N Y Acad Sci.* 2010;1184:121-133.
5. Flemming KD, Wiebers DO, Brown Jr RD. The Natural History of Radiographically Defined Vertebrobasilar Nonsaccular Intracranial Aneurysms. *Cerebrovasc Dis* 2005;20:270-279.
6. Passero SG, Rossi S. Natural history of vertebrobasilar dolichoectasia. *Neurology.* 2008;70(1):66-72.
7. Baran B, Kornafel O, Guziński M et al. Dolichoectasia of the circle of Willis arteries and fusiform aneurysm of basilar artery - case report and review of the literature. *Pol J Radiol.* 2012;77(2):54-59.
8. Pico F, Jacob MP, Labreuche J et al. Matrix metalloproteinase-3 and intracranial arterial dolichoectasia. *Ann Neurol.* 2010;67(4):508-515.
9. Brisman JL, Song JK, Newell DW. Cerebral aneurysms. *N Engl J Med.* 2006;355:928-939
10. Del Brutto VJ, Ortiz JG, Biller J. Intracranial Arterial Dolichoectasia. *Frontiers in Neurology.* 2017;8:344.
11. Hajj-Ali RA, Calabrese LH. Diagnosis and classification of central nervous system vasculitis. *J Autoimmun.* 2014;48-49: 149-152.
12. Ince B, Petty GW, Brown RD Jr et al. Dolichoectasia of the intracranial arteries in patients with first ischemic stroke: a population-based study. *Neurology.* 1998;50(6):1694-1698.

13. Bogouslavsky J, Regli F, Maeder P et al. The etiology of posterior circulation infarcts: A prospective study using magnetic resonance imaging and magnetic resonance angiography. *Neurology*. 1993; 43(8):1528-1533.
14. Wolters FJ, Rinkel GJE, Vergouwen MDI. Clinical course and treatment of vertebrobasilar dolichoectasia: A systematic review of the literature. *Neurol Res*. 2013;35(2):131-137.
15. Smoker WR, Price MJ, Keyes WD et al. High-resolution computed tomography of the basilar artery: 1. Normal size and position. *AJNR Am J Neuroradiol*. 1986;7:55-60.
16. Lin Y-W, Chen C-H, Lai M-L. The dilemma of treating vertebrobasilar dolichoectasia. *Clin Pract*. 2012;2(4):e84.
17. Gutierrez J, Bagci A, Gardener H et al. Dolichoectasia diagnostic methods in a multi-ethnic, stroke-free cohort: Results from the northern Manhattan study. *J Neuroimaging*. 2014;24(3):226-231.
18. Pico F, Labreuche J, Touboul PJ et al. Intracranial arterial dolichoectasia and its relation with atherosclerosis and stroke subtype. *Neurology*. 2003;61(12):1736-1742.
19. Pico F, Labreuche J, Touboul PJ et al. Intracranial arterial dolichoectasia and small-vessel disease in stroke patients. *Ann Neurol*. 2005; 57(4):472-479.
20. Kumral E, Kisabay A, Ataç C et al. The mechanism of ischemic stroke in patients with dolichoectatic basilar artery. *Eur J Neurol*. 2005; 12(6):437-444.
21. Rautenberg W, Aulich A, Röther J et al. Stroke and dolichoectatic intracranial arteries. *Neurol Res*. 1992;14(2 Suppl):201-203.
22. Zis P, Fragkis S, Lykouri M et al. From basilar artery dolichoectasia to basilar artery aneurysm: Natural history in images. *J Stroke Cerebrovasc Dis*. 2015;24(5):e117-119.
23. Nakatomi H, Segawa H, Kurata A et al. Clinicopathological study of intracranial fusiform and dolichoectatic aneurysms: Insight on the mechanism of growth. *Stroke*. 2000;31(4):896-900.
24. Kasantikul V, Suwanwela N, Pongsabutr S. Magnetic resonance images of brain stem infarct in periarteritis nodosa. *Surg Neurol*. 1991;36(2):133-136.
25. Rosenberg MR, Parshley M, Gibson S et al. Central nervous system polyarteritis nodosa. *West J Med*. 1990;153(5):553-556.
26. Blaes F. Diagnosis and therapeutic options for peripheral vasculitic neuropathy. *Ther Adv Musculoskelet Dis*. 2015;7(2):45-55.
27. Yang HC, Lee S, Kim W et al. Spontaneous perirenal hematoma due to multiple renal artery aneurysms in a patient with presumed polyarteritis nodosa. *Vasc Med*. 2012;17(6):427-428.
28. Garg SK, Mohan S, Kumar S. Diagnostic value of 3D contrast-enhanced magnetic resonance angiography in Takayasu's arteritis a comparative study with digital subtraction angiography. *Eur Radiol*. 2011, 21(8):1658-1666.
29. Golovine SG, Parikh S, Lu L. A case of polyarteritis nodosa presenting initially as peripheral vascular disease. *J Gen Intern Med*. 2008;23(9):1528-1531.
30. Lightfoot RW Jr, Michel BA, Bloch DA et al. The American College of Rheumatology 1990 criteria for the classification of polyarteritis nodosa. *Arthritis Rheum*. 1990;33:1088-1093.
31. Howard T, Ahmad K, Swanson J et al. Polyarteritis nodosa. *Tech Vasc Interv Radiol*. 2014;17:247-251.
32. Sansonno D, Dammacco F. Hepatitis C virus, cryoglobulinaemia, and vasculitis immune complex relations. *Lancet Infect Dis*. 2005; 5(4):227-236.