UTILITY FUNCTIONAL MAGNETIC RESONANCE IMAGING IN CHILDREN WITH EPILEPSY

Dr. Oana Tarta-Arsene[1], Fizician Florin Preoteasa[2], Dr. Sanda Magureanu[1], Psiholog Mirela Agavriloaie[1], Dr. Cristina Haritina Motoescu[1], Dr. Eugen Tarta-Arsene[2]

[1]Department of Pediatric Neurology, "Al. Obregia" Clinical Hospital
[2]Radiology Clinic Medix, "Victor Babes" Diagnostic and Treatment Center

ABSTRACT

Evaluation of brain imaging has evolved over the past 15 years, moving from analysing the structure to function through functional magnetic resonance imagery (fMRI). This investigation in children with epilepsy is made in order to understand brain functional areas and the function of epileptic brain and for surgery planning. In this article we present the usefulness and limitations of functional MRI to children diagnosed with epilepsy.

Key words: children, epilepsy, fMRI

DATA ABOUT EPILEPSY

Epilepsy (Greek word: "epilambaneim" means surprise, referring to the sudden and unexpected feature of epileptic seizure) is a chronic cerebral disease with multiple etiologies characterized by recurrence of different epileptic seizures, which are spontaneously, without any trigger. The recurrence could be the result of cerebral structure abnormality or genetic predisposition. In many cases both are intricate (1).

The epileptic seizure isn't synonymous with epilepsy, even both means a transitory dysfunction of brain secondary to abnormal, excessive cortical neuronal excitability. From the clinical point of view, epileptic seizure as intermittent, sudden, stereotypic event could have different forms (motor, sensitive, sensorial or psychic with or without loss of consciousness), different severity, all this depending on the cerebral zone implicated in the epileptogenic focus. An epileptic seizure could be only occasional secondary to metabolic imbalances, trauma, infections etc.

Epilepsy implies more than two seizures or one epileptic seizure with epileptiform discharges on EEG, all these show the tendency to recurrence. Putting clinical data regarding the age, neurological and mental exam, epileptic seizure's aspect with lab investigations EEG and imagistic exams, we can correlate the semiology with etiology, making the correct epileptic syndrome. Each epileptic syndrome has specific therapeutic and prognostic implications (2).

The incidence of the disease shows a higher rate in the first decade, than decreases progressive in the second decade with the lowest incidence from 30-50 years of age, and then progressive increasing in older persons (3).

Despite of many progress in the last decades in epileptology, the etiology of multiple seizures remains insufficient known. In general, it is consider that epilepsy is determined by interactions between genetically factors with neuronal hyper excitability with structural factors from pre, intra, peri and postnatal period. The predominance of some or others provocative factors made idiopathic epilepsy

Author for correspondence:
Oana Tarta-Arsene, MD, "Al. Obregia" Clinical Hospital, 10-12 Berceni Avenue, District 4, Bucharest, Romania
email: otartaarsene@yahoo.com

(genetically factors) or symptomatic epilepsy (acquired factors). The demonstrable causes are different depending on patient's age. The list is very long with cerebral tumors in general benign, cortical malformations either structural or neuronal migration disorders as cortical dysplasia, or vascular as cavernoma or post-stroke's scars.

Evaluation of the patient with presumptive epilepsy implies anamnesis data with clinical neurological and mental exam. Lab tests are blood tests, which search the general state of the child and the specific exams for epilepsy. These are investigations which evaluate the normal and epileptiform cerebral activity as electroencephalography and investigations which evaluate cerebral structure as computer tomography or magnetic resonance imaging (MRI). For interpretation of imagistic data it is important to make the correct semiological and syndromological diagnosis, and then to ask the radiologist a specific imaging evaluation of cerebral structure.

IMAGISTIC INVESTIGATIONS OF CHILDREN WITH EPILEPSY

Cerebral computer tomography (CT) is facile, relative cheap investigation available in short time. Not having so many contraindications, being compatible with pace-maker, ventilators, it becomes the emergency evaluation method for acute cerebral disorders. When it is completed with enhancement, could demonstrate cerebral tumors, focal infections as abscess and blood or calcifications. CT could miss smaller lesions inclusive tumors, malformations, hippocampus sclerosis or cortical malformations. A negative cerebral CT allows us little information in children with epilepsy. So, it is recommended only after acute epileptic seizures with focal neurological signs or as a complementary exam of cerebral MRI for evaluation of calcifications. Cerebral CT is just an alternative to MRI when the last is not available, but with larger limits related to multiple cerebral disorders that could be missed (4).

Cerebral MRI is the ideal investigation of the cerebral structure for patients with epilepsy. It's being using a very powerful magnetic field, with radio frequencies and a computer for detailed analysis of cerebral images. Sections through different plans are made, with later analysis of images. The time of acquisition of longer comparing to CT, but the resolution is much higher.

Minimum standard differ depending on economical and social factors of different countries. MRI is preferred, even as first intention to child with epilepsy. The ideal investigation is using an advanced machine as 1,5 T or 3 T. Evaluation technique includes minimum 2 plans (axial, coronal) with smaller sections of entire brain in T1, T2 sequences (Figure 1). In rare cases, administration of enhancement could bring supplementary information. Other sequences, as FLAIR (fluid attenuated inversion recovery) could have an important role in the case of normal standard imaging or to clarify a focal abnormality (4).

Besides qualitative analysis, in evaluation of some regions as hippocampus is necessary quantitative analysis as volumetric measurements.

MRI has some limits. First, the patient has to stay into a closed spaced, not moving for a period of time and this could be pretty an impediment at least for children or for claustrophobic persons (fear of closed spaces). For dealing with these problems, mild sedatives could be recommended.

Women should inform doctor or technician about the possibility of being pregnant. MRI was used for scanning the humans from 1980 without any pathological effect on pregnant women or fetuses, but

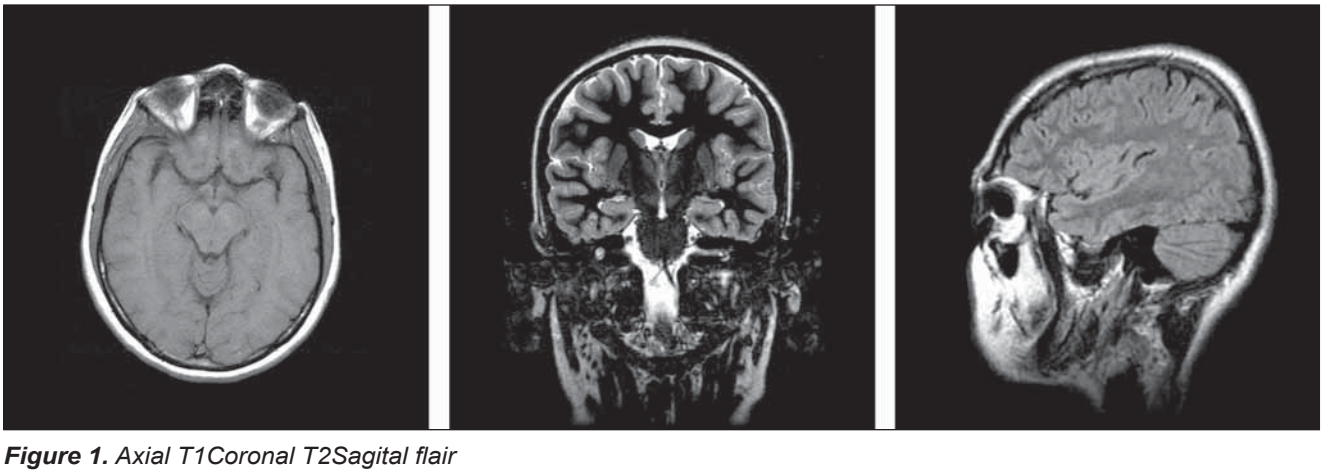

Figure 1. *Axial T1Coronal T2Sagital flair*

because the magnetic field is very strong, this investigation should be used only when the therapeutic potential exceeds the risk.

Also because of the magnetic field, jewelry of other magnetic or electronic accessorize should not be worn during the investigation. These are: earrings, watch, credit cards, hearing aids, hairpins, metal zippers, mobile prostheses, glasses, pens etc (4).

Examination through MRI is not possible for persons with these implants: internal defibrillator or pacemaker, cochlear implant, certain types of clips used in cerebral aneurysms.

Patients who have different tattoos that contain iodine, during examination by MRI can overheat, but these events are rarely a problem. Dental fillings and braces usually are not affected by magnetic field, but can distort the images, so the radiologist should be aware of their existence.

Cerebral MRI has particular indications in patients with epilepsy. So, the MRI is a first intention investigation of patients with epilepsy at any age with focal debut of seizures. In case of generalized or unclassifiable seizures in the first year of life or adulthood the brain MRI is helpful in assessing brain structure. The recommendation extends to patients in whom clinical examination focal neurological deficits are detected. The remaining patients with normal neurological examination and generalized seizures cerebral MRI is indicated in case of changes in response to antiepileptic drug therapy, even poor control after the first antiepileptic administered or when after a period of complete control, seizures recur or change in seizure's aspect (4).

In patients with epilepsy resistant to antiepileptic treatment the opportunity for epilepsy surgery is being assessed.

Figure 2

Pre surgical evaluations consist in long term monitoring video-EEG for recording the ictal and interictal trace, and functional neuroimagistic exams. These are: fMRI, MRS (spectroscopy through magnetic resonance), SPECT (single photon emission computed tomography), PET (positron emission tomography). Their purpose is to delineate the structure and function of a probably epileptic region and other distance abnormalities, more accurate evaluation of the brain lesion. The second purpose is to identify brain regions important in terms of functional area such as primary motor, sensory, language or memory and the relationship with the epilepsy.

FMRI IN CHILDREN WITH EPILEPSY

FMRI is an imagistic investigation which evaluates different cerebral activated zones. The images are acquired with 1.5T or 3T because of the optimal ratio signal-noise. The majority of the investigators are using echoplanar images with measurements the differences of the blood oxygenation levels (BOLD – blood oxygenation level contrast measurements) between the activation and rest state. For an ideal fMRI first a morphological MRI should be done, and after that fMRI for eventual overlapping the images of these two investigations. fMRI provides a higher resolution on vascular changes in detriment of structural abnormalities, with distortions of images around structures as sinuses (Figure 2) (5).

For activation of different cerebral functional zones, the child is positioned in the magnetic field and depending on which area is being evaluated, different activities are made for 30 seconds, followed by rest of 30 seconds, and then all the tasks are repeated several times. So, for evaluation of hand motor area, the child has to move the fingers of hand, for language area he has to respond to different questions depending on which language are is being evaluated or for the memory task he is dealing with different activation tasks of memory. Because the hemoglobin has different magnetic signal depending on oxygenation state, through BOLD technique (blood oxygen level-dependent functional magnetic resonance). The results are statistically prelucrated through statistical parametric mapping (SPM) for verifying the statically significance (6).

Currently there are no clear recommendations about clinical indications of fMRI.

In patients with epilepsy is recommended primarily for mapping areas of functionally important in order to avoid invasive investigations of intracarotidiene injection of sodium Amobarbital (WADA test). This is recommended for assessing hemispheric dominance of language area activation.

To locate the area of language activation we are using tasks such as generating a verb (a verb assigning a given noun), thereby activating all areas including association ones, but predominantly frontal lobe. But, because activation is bilateral, with a predominance of one, the results are analyzed statistically between the two hemispheres in order to establish dominance – lateralisation index (LI). This is the formula LI = (LR) / (L + R), where L and R represents the number of activated voxel in the left hemisphere (L) and right (R). A positive index corresponds to a left hemispheric dominance LI> 0.20 and negative index is a dominant right-LI <-0.20.

Symmetrical or bilateral activation occurs when -0.20 <LI <0.20 (7).

In case of evaluation of other brain areas involved in language, such as temporal lobe tasks we are using different semantic tests such as synonyms or rhymes. We must remember that not all activated areas play a crucial role in the execution task. Similarly, there are areas that are not activated but are involved in that function.

Studies used so far, validated the data obtained for the area location to determine lateralisation of language and determined the dominant hemisphere, are compared now to other invasive maneuvers and they've demonstrated the similar results (8).

fMRI can be useful when the patient has an epileptogenic lesion in an anatomical area that is generally important in terms of functionality. To assess the relationship between them with the task, fMRI is recommended in planning your surgery.

As the only imaging procedure to assess brain function in real time, has a good potential for research into both causes and effects of epileptic seizures. Such studies were conducted simultaneously recorded EEG data and fMRI for both interictal and ictal changes. The aim is to understand the place of onset of seizures such absences or simple partial, or the zones related to epileptiform encephalopathies (with significant electroencephalographic changes).

Still for research purposes fMRIf was used to highlight the evolution of areas involved in memory, affection, attention, etc. (9).

In children diagnosed with epilepsy fMRI has certain peculiarities. Primarily, related to the technique, because it's being applicable only to children over a certain age (generally over 8 years) with normal intellect. The authors did investigate the language area with fMRI in seven preschool children, the youngest being five years. Intellect has to be within normal limits, to be cooperative so that they can make demands in a short time. We know that epilepsy as a chronic disease of neural circuits and especially in children could have consequence in cognitive abilities and personality, and that could even more lower the fMRI addressability.

Most studies with fMRI in patients with epilepsy have been performed on adults, and the methodology can not completely overlap in children, especially in the youngest ones. Even more, because in children we investigate a brain in developing, the neuroplaticity could change the results in time for the same disease.

Though it was demonstrated in children with epilepsy atypical language dominance, with more often representation in the right cerebral hemisphere or bilaterally compared with adults with epilepsy. The organization of language areas is not the same but a much larger area due to poor maturazitation of neural networks (10, 11).

All these features are related to child neuroplasticity, making it special for us as doctors trying to understand the causes and evolution of a disease in a developing brain (12).

PRESENTATION OF CLINICAL CASE

Vlad is a 9-year-old boy, left handed, normal intellect that comes in the department of pediatric neurology because since four months he has some events when is awake, a weird smell ("poisoned honey"), sometimes accompanied by a particular flavor and then he starres, has some chewing automatisms, left upper limb automatisms with dystonic position of the right upper limb, all this for 1 minute, followed by headache and sleep. Manifestations are common 5-9/zi, with a maximum free period of 2-4 days.

Given the stereotypical appearance of events with loss of consciousness, short duration, followed by sleep, the events are probably epileptic seizures. Antiepileptic treatment has been tried in therapeutic doses in monotherapy or combination, with carbamazepine, oxcarbazepine, valproate, levetiracetam, topiramate, all in therapeutic doses but without result.

The family is healthy, but a paternal grandfather with hemiparesis at age 17.

Vlad has no history of perinatal distress or psycho-motor development delay. From age 4, Vladut says that he still has moments in kindergarten, when he was bothered by noise or he felt a weird taste and smell, sometimes with headache, all these events had variable duration, followed by sleep. Clinical signs were considered to be digestive nature and are investigated in this respect. She consulted the family doctor, pediatrician, gastroenterologist, dentist without finding apparent cause of these events.

Neurological examination is normal and shows the psychological IQ-120 (above average level) with a capacity of medium-level verbal association and retrieval in normal activity. His behavior is uninhibited, in need of affirmation and struggle to comply with the rules and social boundaries; however these aspects increased lately (possibly a reaction to the disease through a defensive mechanism).

EEG shows an interictal background with asymmetric rhythm, normal in the right hemisphere and intricated abnormalities as slower with epileptiform discharges in left temporal derivations. There were no seizures registered on EEG.

The brain MRI was performed with and without gadolinium administration (Figure 3, 4).

Native brain MRI investigation and post contrast showed a parenchymal left temporal lesion (maximum size 3 / 1, 9 / 1, 3 cm) neomogenous with T1 and T2 isosignal with CSF and discreetly hipersemnal STIR which outlines in a horizontal fluid axially. Adjacent to this there is a lesional process evidenced by a signal node tissue, discrete heterogeneous gadolinofil (size 1.7 / 1.5 cm) with superficial topography. There is a third lesion with charactheristics of cortical dysplastic changes which implicates hippocampus. It can be seen also a discrete localized edema in white matter of the basal portion of the temporal lobe. Easy fingerprint left temporal horn by the previously described lesions.

Given the large left temporal brain lesion in a left handed patient, the hemispheric dominance it's an issue. Thus, functional MRI is recommended for the area of language in order to evaluate hemispheric

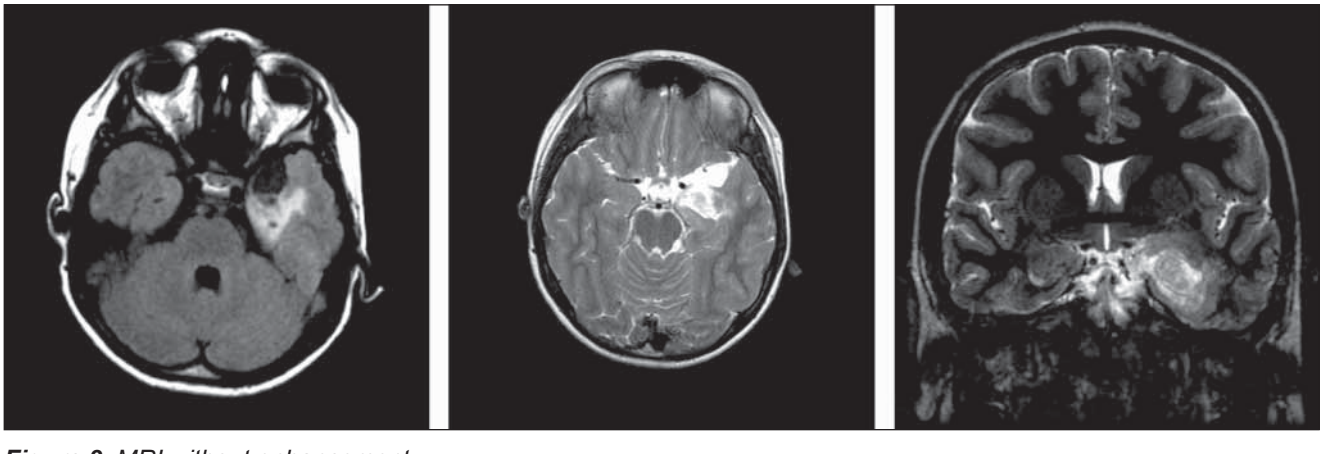

Figure 3. *MRI without enhancement*

Figure 4. *MRI with enhancement*

dominance and the anatomical rapport between the lesion and temporal language area. For evaluating the cerebral hemispheric dominance, he did languange activation method by verb generation and hand motor areas. Since the verb-generation appears to stimulate the frontal lobe predominant areas for recording temporal lobe language areas is done a semantics task with synonyms and rhymes. For all methods of activation it was used a model that involves the activation blocks of 30 seconds and 30 seconds break blocks.

Acquired images were processed SPM5 software (Statistical parametric mapping). Before statistical analysis the results were corrected for motion pictures.

Over hrf function was superimposed acquired an ideal box-car function. Statistics: Statistical threshold: p (corrected for multiple comparisons according to random field theory, Friston et. Al.,1994) <0.05 (13).

Motor activation task revealed lateralisation index of 0.85 for the left hand – right hemispheric dominance. Lateralisation index was calculated according to published techniques (10). The report LI = (C-I) / (C + I), where LI = lateralisation index C – number of controlateral activations, I – number of ipsilateral activations.

Following activation to the task execution protocol by the verb generation – these activations were observed in the left temporal lobe: Superior Temporal gyrus, Middle Temporal gyrus, Angular gyrus and Superior occipital gyrus. Activated Brodmann area: BA 39 – involved in translating the words written in an internal monologue.

Following activation to the task execution by the synonymous word these activations were observed in the left temporal lobe: Superior Temporal gyrus, Middle Temporal gyrus, Supramarginal gyrus, Superior Temporal gyrus, Inferior parietal lobules. Brodmann areas activated: BA 22 – role in speech processing so it can be understood as language, BA 39 – involved in translating the words written in an internal monologue, BA 40 – involved in reading on phonological and understood meanings.

Following activation to the task execution protocol by the rhymes on these activations were observed in the left temporal lobe: Middle Temporal gyrus, Superior Temporal gyrus. Angular gyrus. Activated Brodmann area: BA 39 – involved in translating the words written in an internal monologue.

Wernicke area was on the right superior temporal gyrus.

Blop activation sites for all three tasks are shown in the pictures below – Figure 5 (4)

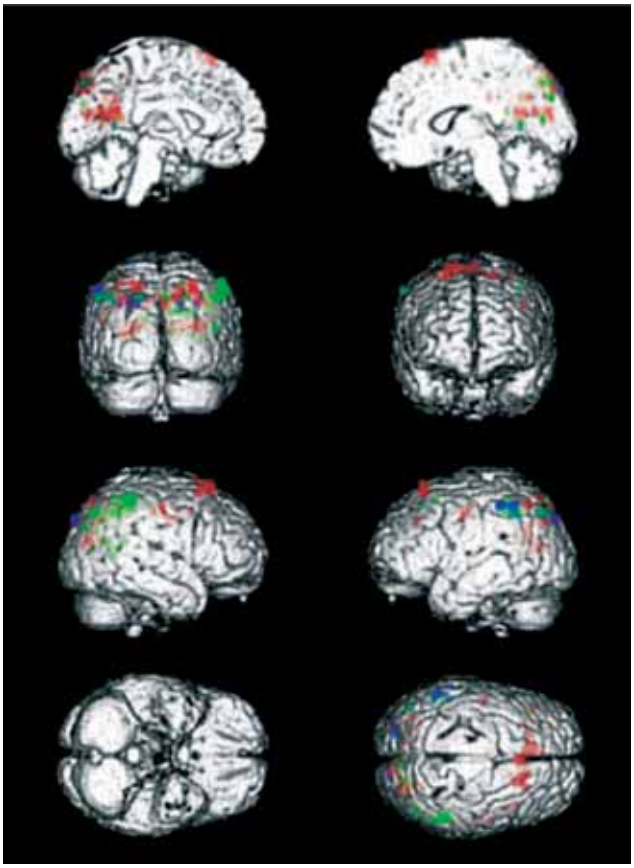

Figure 5. *FMRI: Blop's red – verb generation; Blop's blue – synonyms Blop's Green – rhymes; After history (focal onset seizures in left temporal lobe), clinical examination and lab tests (lesional and epileptiform EEG discharges in left temporal lobe tumor with MRI-evidenced in the brain), the diagnosis of symptomatic focal epilepsy in left temporal lobe resistant to treatment and raise the question of neurosurgical intervention.*

After evaluation through fMRI it was concluded that the dominant hemisphere of Vlad is right, and the intervention can be done without any particular concerning. Vlad was operated, the tumor was removed completely, and extemporaneously pathological examination showed pilocitic astrocytoma after two weeks he has no epileptic seizures and without cognitive deficits. The final pathological exam will show it was a dual pathology, like the radiologist described.

CONCLUSIONS

FMRI is an investigation that in collaborative with clinical, neurological, psychological, EEG and structural MRI could help us understand the connection between brain structure and function. There

is a need for a multidisciplinary team and last but not least to interpret the results.

The clinical applicability and usefulness of fMRI in children with epilepsy is not fully defined at present, but it could be a starting point for further research related to cause – epileptiform abnormalites and result – neuroplasticity.

REFERENCES

1. **Aicardi J.** (1994) – Epilepsy in Children, second edition, Raven Press;
2. **Dreifuss F. E.** (1989) – Clasification of Epileptic Seizures and the Epilepsies, Pediatric Clinics of North America;
3. **Roger J. et colab** (1992) – Les syndromes epileptiques de l'enfant et de l'adolescent, John Libley;
4. **Neuroimaging subcomission of the International League Against Epilepsy** – Commission on Diagnostic Strategies Recommendations for Functional Neuroimaging of Persons with Epilepsy, *Epilepsia* 41(10): 1350-1356, 2000;
5. **Arndt S., Gold S., Cizadlo T., Zheng J, Ehrahardt J.C. and Flaum M,** 1997: A method to determine activation thresholds in fMRI paradigms, Psychiatry Res. *Neuroimaging*, 75:15-22;
6. **Arndt S., Cizadio T., Andreasen N.C., Heckel D., Gold S. and O'Leary D.S.** 1996: Tests for comparing images based on randomization and permutation methods, *J Cereb Blood Flow Metab,* 16:1271-1279;
7. **Benson R.R., FitzGerald D.B., LeSueur L.L., Kennedy D.N., Kwong K.K., Buchbinder B.R., Davis T.L., Weisskoff R.M., Talavage T.M., Logan W.J., Cosgrove G.R., Belliveau J.W., and Rosen B.R.,** 1999: Language dominance determined by whole brain functional MRI in patients with brain lesions, *Neurology* 52:798-809;
8. **Benson R., Belliveau J., Kwong K., Buchbinder B., Jiang H., Cosgrove R. and Rosen B.,** 1995: Preoperative maping of language cortex with functional MRI, *Hum Brain Mapp*, 351;
9. **Zimine I., Seghier M.L, Seeck M., Laqeyras F.,** 2003: 'Brain activation using triggered event-related fMRI', *Neuroimage* 18 (2003): 410-415;
10. **Szaflarski J.P, Holland S.K, Schmithorst V.J, Byars A.W:** „An fMRI study of language lateralization in children and adults", *Hum Brain Mapp*, 2006 March; 27 (3): 202-212;
11. **Yuan W et colab:**'FMRI shows atypical language lateralization in pediatric epilepsy patients', *Epilepsia* 2006, March: 47(3): 593-600;
12. **Shaywithz S.E., Shaywitz B.A., Pugh K.R., Fulbright R.K., Constable R.T., Mencl W.E., Shankweiler D.P., Liberman A.M., Skudalrski P., Fletcher J.M., Katz L., Marchlone K.E., Lacadie C., Gatenby C. and Core J.C.** 1998: Functional disruption in the organization of the brain for reading in dyslexia
13. **K.J. Friston, K.J. Worsley, R.S.J. Frackowiak, J.C. Mazziotta, and A.C. Evans.** Assessing the Significance of Focal Activations Using their Spatial Extent. *Human Brain Mapping*, 1:214-220, 1994.