ANATOMIC, CLINICAL AND PATHOPHYSIOLOGIC CORRELATES IN ACUTE BILATERAL PARAMEDIAN THALAMIC INFARCTS

M. Alaicescu[1], A. Nistorescu[1], Gh. Popa[1], L. Botezatu[1], A. Dediu[1], E. Ifrim[1], Indra Mihaita[2]

[1]National Institute of Neurology and Neurovascular Diseases „Prof. Dr. V. Voiculescu“, Neurology Service, Bucharest

[2]„Medinst“ Center for Diagnostic Imaging, Bucharest

ABSTRACT

We describe three pacients in whom cerebral imaging showed bilateral paramedian thalamic infarcts inconstantly associated with bilateral rostral mesencephalic lesions ; in accordance with the radiological findings, these pacients also displayed a characteristic clinical picture. Although the pathogenesis of the syndrome is variable, the most likely and therefore first to be considered is the occlusion of an azygous arterial trunk with bilateral thalamic distribution, commonly known as the artery of Percheron; this peculiar artery is no more than a rare yet normal anatomic variant of the regional blood supply.

Key words: thalamus; paramedian; infarcts; Percheron artery

Bilateral thalamic infarcts are well known to occur only with low frequency amongst different subtypes of strokes; when these infarcts involve the medial aspects of the thalami in a relatively symmetrical pattern with or without the simultaneous involvement of the rostral midbrain bilaterally, this usually points out to the occlusion of the artery of Percheron (1), a solitary arterial trunk that arises from one of the proximal segments of a posterior cerebral artery and supplies the paramedian thalamus, subthalamus and certain structures of the rostral midrain.

CASE PRESENTATION

Case No. 1

A 66- year- old woman with a history of chronic atrial fibrillation and ischemic heart disease was admitted to the emergency room of our hospital with a prolonged episode of unresponsiveness preceded by impairment of vision; as she slowly regained consciousness, some facial asymmetry, a state of drowsiness, apathy and indifference are immediately noticed by the patient's family. Physical examination revealed mild right facial palsy and right hemiparesis along with disarthrya and disorders of ocular motility such as divergent strabismus of the left eye and vertical gaze palsy mostly on upward gaze. The most prominent findings were however a state of persistent somnolence, severely impaired memory and lack of initiative.

Because the CT scan was nondiagnostic, we performed an MRI of the brain which showed bilateral (slightly asimmetrycal) paramedian thalamic together with bilateral periaqueductal (mesencephalic) hiperintensities on T2-weighted and FLAIR images (figure 1); the large arteries of the posterior circulation were shown to be fully patent on the angio-MRI sequence of the imagistic examination.

During hospitalization, the patient fully (but slowly) recovered the disorders of ocular motility, only partially the facial palsy but was, nonetheless, left with disordered behavior and cognitive deficits of a moderate to severe degree of intensity, a mental status closely resembling (in the authors' opinion) the so-called „thalamic dementia“.

Case No. 2

A 59-year-old woman, with a history of hypertension and ischemic heart disease was admitted to the intensive care unit of our hospital with a dramatic onset of a comatose state. The pupils were enlarged, asymmetrical and slowly reactive, the deglutition was abolished and the gag reflex markedly diminished; application of nociceptive stimuli evoked symmetrical defense response of the limbs and the tendon reflexes were also normal. The comatose state was given 6-7 points on the Glasgow Coma Scale (GCS).

The electroencephalogram showed diffuse background slowing (reflecting a deep midline structural

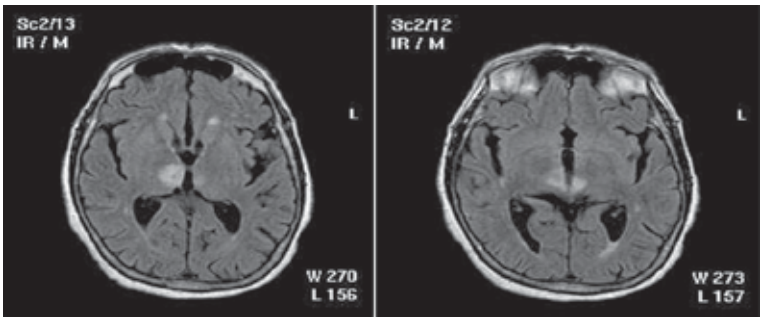

Figure 1
LV, 66 year old female FLAIR MRI axial images of the brain

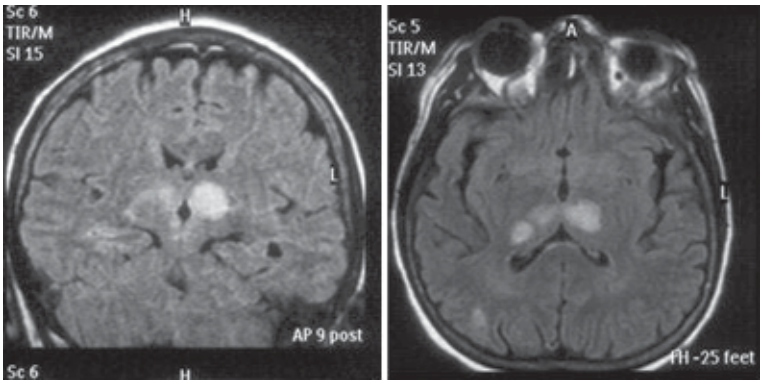

Figure 2
TP, 59 year old female axial and coronar FLAIR MRI images

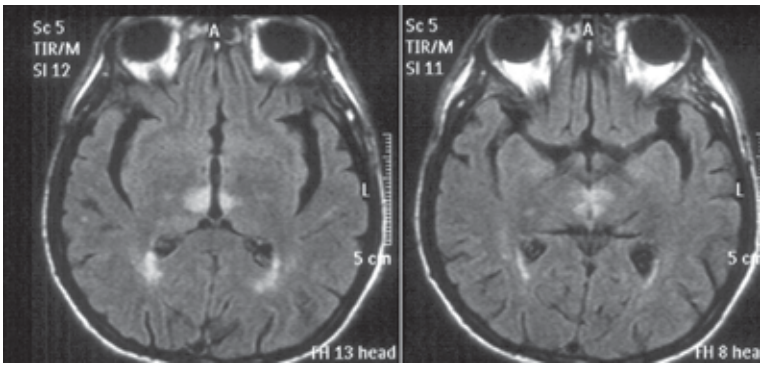

Figure 3
IM, 53 year old male FLAIR MRI axial images of the brain

abnormality), while echocardiography was consistent with sequelae of myocardial infarction. Brain MRI proved to be decisive showing T2-hyperintense lesions consistent with the diagnosis of acute bilateral paramedian thalamic infarction and also older ischemic lesions in the deep temporal and occipital lobes on the right side (figure 2); the brain lesions mentioned above are suggestive of multiple ischemic embolic lesions most likely from a cardiac source.

In accordance with the presumed pathogenetic mechanism of the stroke the authors started parenteral nonfractionated heparine followed by oral anticoagulation under which the patient made a very slow transition to a stuporous state from the initial comatose one. Later still, gait and reduced output, slurred speech became possible again but only under repeated external stimulation, the patient lacking the initiative to carry on these simple activities. The authors remarked also the persistence of partial bilateral ptosis.

Case No. 3

A 53-year-old hypertensive man was found unresponsive in his house. On admission to our hospital, the physical examination showed an unresponsive, stuporous patient (7 points on the Glasgow Coma Scale) with no apparent motor deficits; his pupils were enlarged, asymmetrical and practically unresponsive to light and he also displayed intermittent vertical gaze palsy.

The CT scan of the brain revealed no more than diffuse, confluent hypointensities of the periventricular white matter (leukoareosis); we decided then to perform brain MRI which showed T2 and FLAIR ischemic hyperintensities with bilateral, paramedian symmetrical thalamic distribution and caudal extension in the subthalamus and in the periaqueductal grey matter of the midbrain as well as chronic, diffuse microangiopathic lesions, seen also in the CT scan (figure 3). Ultrasound studies revealed septal akinesia and spontaneous contrast in the cavity of left ventricle together with aortic arch and internal carotid arteries atheromatosis.

Under parenteral heparinic therapy the patient's status improved slowly; the initial comatose state gave way to marked abulia with periods of drowsiness intersperssed with periods of restlessness, uttering of nonintelligible sounds and failure to execute the examiner's simplest commands.

DISCUSSION

Bilateral symmetrical infarctions of the brain are more likely to appear in the infratentorial than in the supratentorial compartment (2). In the latter location, the clinician has to deal mainly with two possibilities:

1. bilateral infarcts in the territory of both anterior cerebral arteries most likely resulting from occlusion of an azygous arterial trunk with bilateral distribution and
2. bilateral thalamic infarctions explained by a more complex pathogenesis detailed below.

The thalamus receives its blood supply from two main arterial sources: a secondary one from the anterior circulation through the thalamoperforating arteries, branches of the posterior communicating arteries and most importantly from the posterior circulation through the posterior cerebral artery; the latter arterial trunk gives rise to four distinct vascular branches that specifically supply certain nuclear groups in the thalamus: the tuberothalamic arteries, inferolateral, paramedian and posterior coroidian arteries (3).

The paramedian arteries (also known as the thalamoperforating pedicle, the thalamosubthalamic arteries or the posterior internal optic arteries of Duret) represent the superior divisions of the interpeduncular arteries, the latter stemming from the initial (P1) segment („the mesencephalic artery") of the posterior cerebral artery (PCA). These arteries supply a variable extent of the thalamus but principally the dorsomedial nucleus, intralaminar nuclei and the internal medullary lamina and also the subthalamus and parts of the rostral midbrain (2, 3, 4). There are three anatomical variants of the paramedian arteries:

1. Most frequently small but single branches arising from both P1 segments of the PCA,
2. A single common arterial trunk with bilateral thalamic distribution arising from a P1 segment (the so-called artery of Percheron) and
3. An arterial arcade emanating from an artery bridging the two P1 segments.

The presence of bilateral thalamic infarcts in the patients described above is confirmed by the radiological findings and particularly by brain MRI and nonetheless, strongly suggested by the clinical picture of the disease.

Classically, bilateral infarction in the paramedian artery territory may result in an acutely ill patient with altered state of consciousness, confusion, disorientation, somnolence, „coma vigil" frequently progressing to profound coma lasting hours or days. These initial manifestations are usually followed by severe impairment of anterograde and retrograde memory with confabulation and also of autobiographical memory and marked disorientation in time; the latter phenomenon was called „chronotaraxis" by Spiegel (5). The recall of public persons and events remains relatively unaffected, the resulting dysmnestic syndrome being similar to the thiamine-deficient Korsakoff syndrome. The subsequent addition of other neuropsychological deficitis (usually long lasting) in the sphere of cognition, affect and behavior produces a constellation that led to the term „thalamic dementia" (3, 6) – its defining attributes are diminution or lack of spontaneous thinking or mental activity („loss of psychic selfactivation"), apathy, loss of initiative, inappropriate social behavior, impulsivity, even aggressiveness, emotional blunting.

The term „thalamic dementia" is also used to describe the clinical consequences of thalamic lesions in other conditions such as Creutzfeldt-Jakob disease or fatal familial insomnia (7). Elementary neurological signs from lesions of the paramedian artery may also include asterixis, complete or partial vertical gaze palsies, loss of convergence, pseudo-sixth nerve palsies, bilateral internuclear ophtalmoplegia, pupillary abnormalities, even photofobia due to involvement of groups of rostral midbrain nuclei which are supplied by the inferior and middle divisions of the interpenduncular artery.

The authors of the article strongly support the idea that the clinico-radiological picture of the patients presented above is the result of occlusion (most probably embolic) of a single paramedian thalamic artery, best known as the Percheron artery. Occlusion of the Percheron artery may be embolic (as already mentioned) or the result of local thrombosis of microatheromatous plaques (8) located in the walls of the posterior cerebral artery in close proximity with the ostium of the paramedian artery (so-called junctional plaques). One can also think of occlusion of multiple vascular branches (as a result of recurrent embolism, for example) but the thalamic lesions produced in that manner would be most probably successive and asymmetrical, not resembling the symmetrical, simultaneous infarcts seen in our material. Other mechanisms of occlusion of the single Percheron artery that could be reasonably taken into account would be 1. a hemodynamic mechanism (e.g. systemic hypotension) favored by a nonfunctional circle of Willis with secondary distal ischemia in the distal, perforating medium-sized arteries (the Percheron artery falls into this category), 2. distal ischemia in the posterior circulation due to alteration of the normal laminary blood flow in the basilar artery as a result of compartimentation of the vascular lumen by a vestigial septum from the embryological period of life and 3. exceptionally, aneurysms of the basilar apex that can directly block the orifice of

tributary vessels or clots within these aneurysms that may embolize distally in the paramedian arteries (8).

The differential diagnosis also includes the „top of the basilar artery" syndrome but in this condition infarcts tend to involve also the territories supplied by the superior cerebellar and posterior cerebral arteries with a resulting dramatic clinical picture from which the symptoms and signs of bilateral thalamic infarct could no longer be individualised.

Conventional angiography and angio-MRI are of little value in validating the occlusion of the Percheron artery because this is a small-caliber vessel, difficult to be visualized radiologically even when anatomically intact. These explorations are especially useful in the initial evaluation of the role of occlusion of the larger vessels of the posterior circulation in the causation of the syndrome; for example, visualization of a fully patent basilar artery makes the diagnosis of „top of the basilar artery" syndrome very unlikely.

In comparison to ischemic lesions of other cortical-subcortical structures, thalamic stroke has a lower mortality rate and a much better prognosis for recovery of motor deficits as one can easily discern from the evolution of our cases. By contrast, the neuropsychological deficits in various aspects of memory, cognition, emotional response and behavior tend to persist and to interfere greatly with the future social and professional reinsertion of the patient; a considerable source of distress for his or her family will also derive from the lack of initiative, apathy and emotional indifference manifested by the patient.

CONCLUSION

The purpose of this article is to present three patients with a similar clinico-radiological picture highly suggestive of bilateral paramedian thalamic infarction. The authors conclude that this rare clinical entity is most probably due to occlusion (embolic rather than atherotrombotic) of a single arterial trunk with bilateral, symmetrical thalamic distribution called the artery of Percheron. In practice, clinicians often erroneously attribute the syndrome to the occlusion of multiple arterial branches with thalamic distribution, to vasculitis, or even to nonvascular disease of the brain (e.g. infections). Bilateral paramedian thalamic infarction is accompanied by a very characteristic clinical syndrome classically known as „thalamic dementia" that do not develop in cases of unilateral lesions. Although the patients are usually left only with mild motor deficits, they are frequently and severely incapacitated by the long term impairment of neuropsychological functions such as memory, cognition and behavior.

REFERENCES

1. **Percheron G** – Les artères du thalamus humain. *Rev Neurol,* (Paris) 132: 297-307, 309-324, 1976.
2. **Matheus MG, Castillo M** – Imaging of Acute Bilateral Paramedian Thalamic and Mesencephalic Infarcts. *Am J Neuroradiol*, 24: 2005-2008, November/December 2003.
3. **Schmahmann JD** – Vascular Syndromes of the Thalamus. *Stroke*, 2003; 34: 2264-2278.
4. **Carpenter MB** – Core text of Neuroanatomy, 4th edition. 255-296, 448-455, Williams & Wilkins, 1991.
5. **Spiegel EA, Wycis HT, Orchinik C, Freed H** – Thalamic chronotaraxis. *Am J Psychiatry*, 1956; 113: 97-105.
6. **Segarra JM** – Cerebral vascular disease and behavior, I: the syndrome of the mesencephalic artery (basilar artery bifurcation). *Arch Neurol*, 1970; 22: 408-418.
7. **Martin JJ** – Degenerative diseases of the human thalamus. In: Steriade M, Jones EG, McCormick DA, eds. Thalamus, Volume II: Experimental and Clinical Aspects. New York, NY: Elsevier; 1997: 653-687.
8. **Barnett HJ, Mohr PJ** – Stroke, pathophysiology, diagnosis and management, third edition, 513-598, Churchill Livingstone, 1998.